



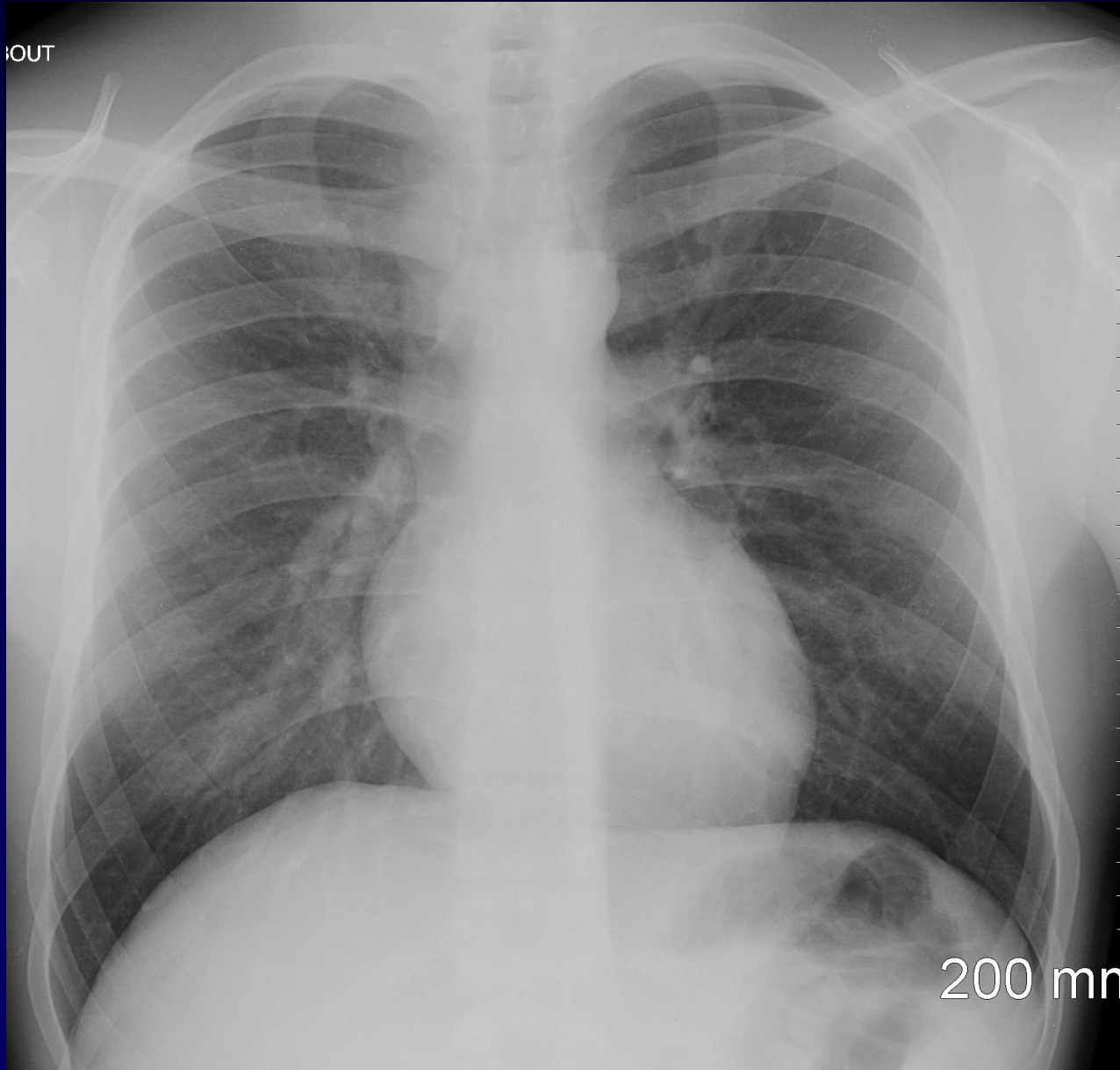
Homme de 25 ans

Etat général altéré

Migrant

Tuméfaction au cou (espace de Gruber)

TDM

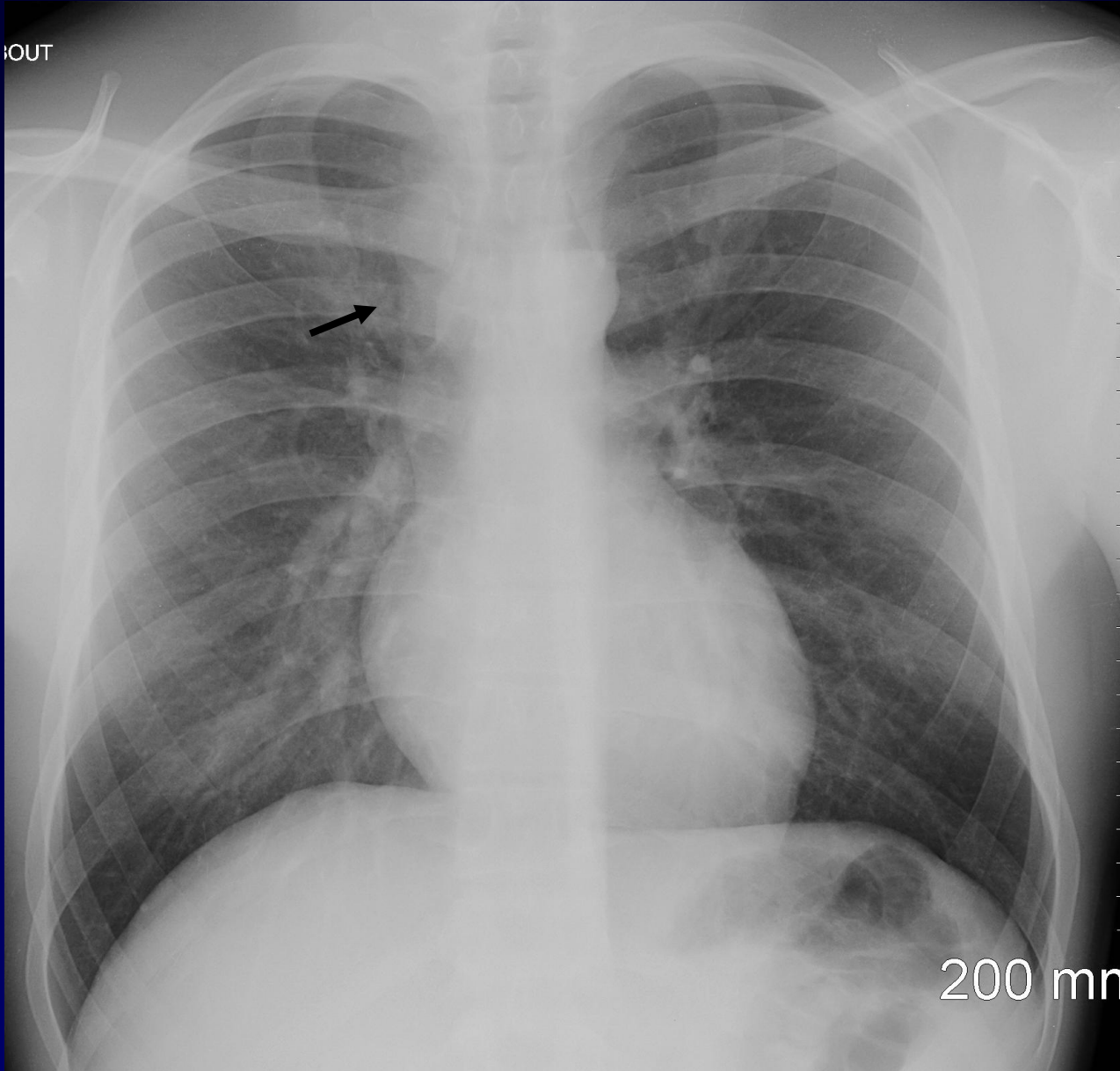


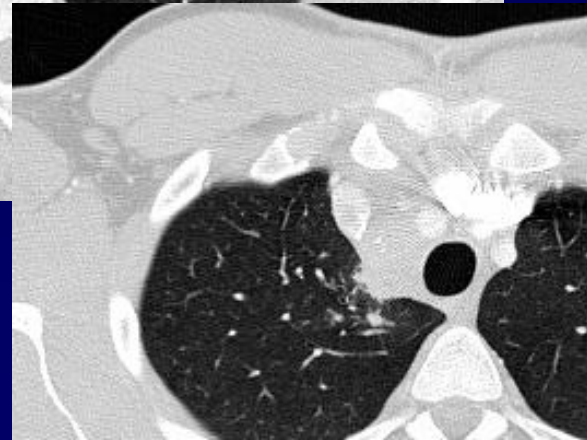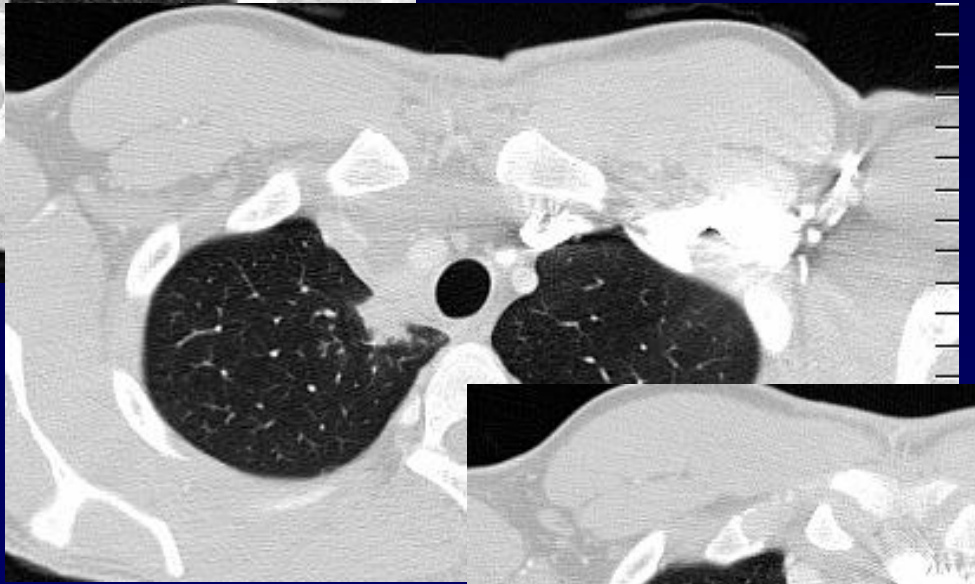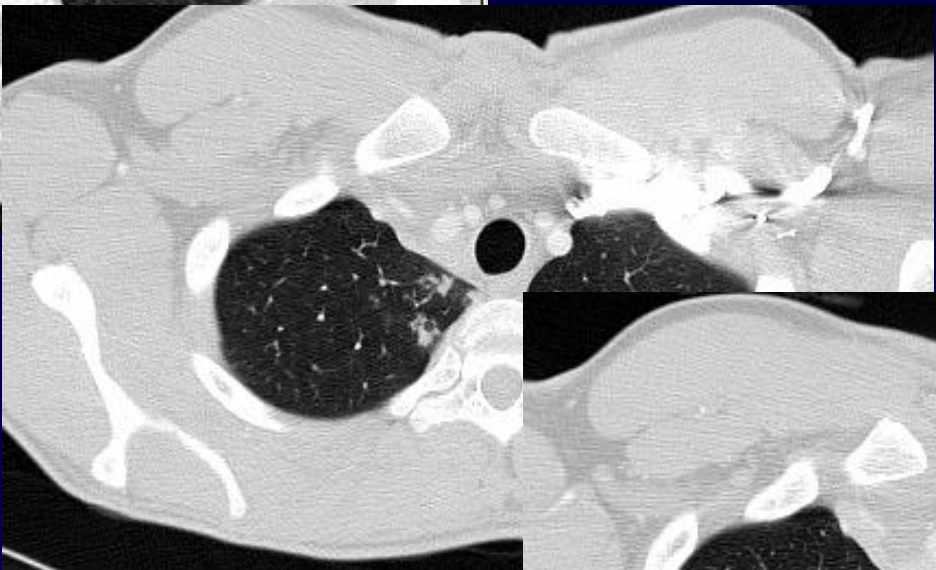
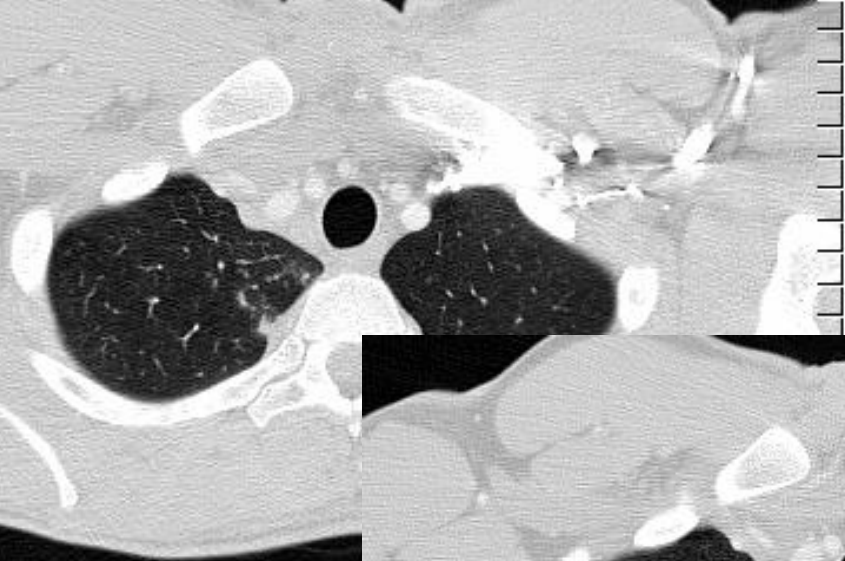
OUT

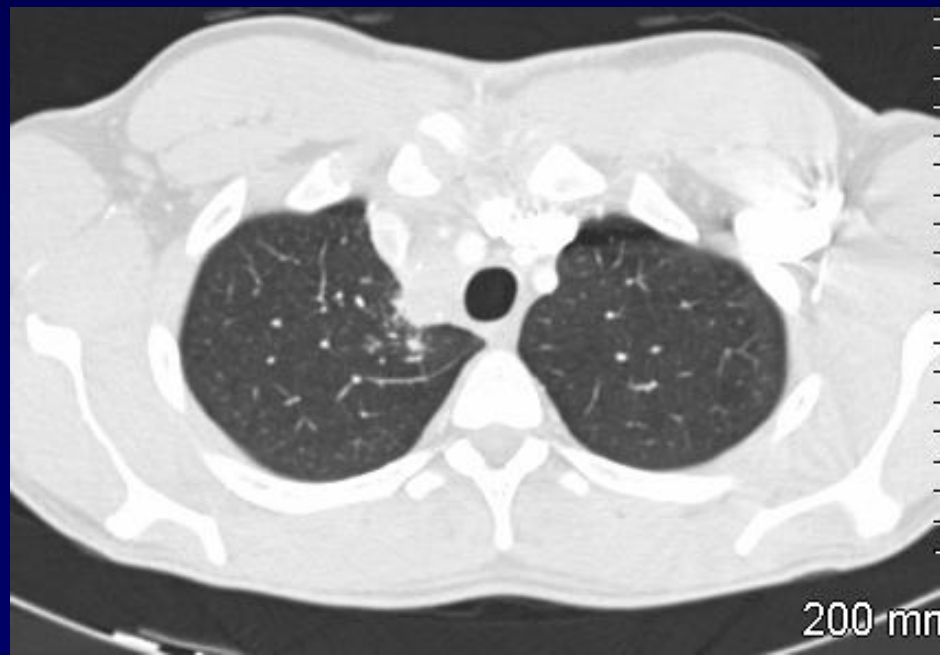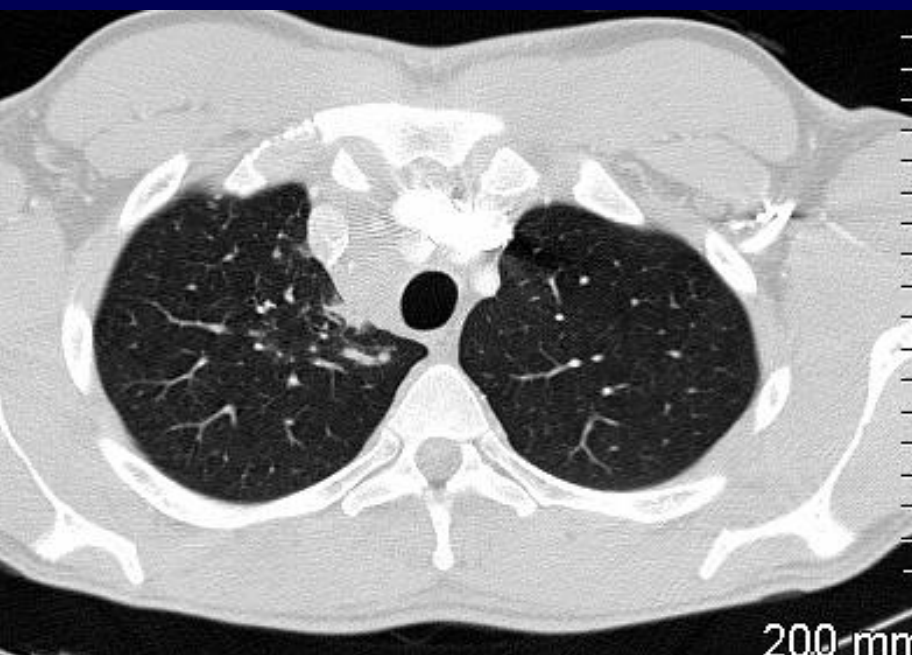
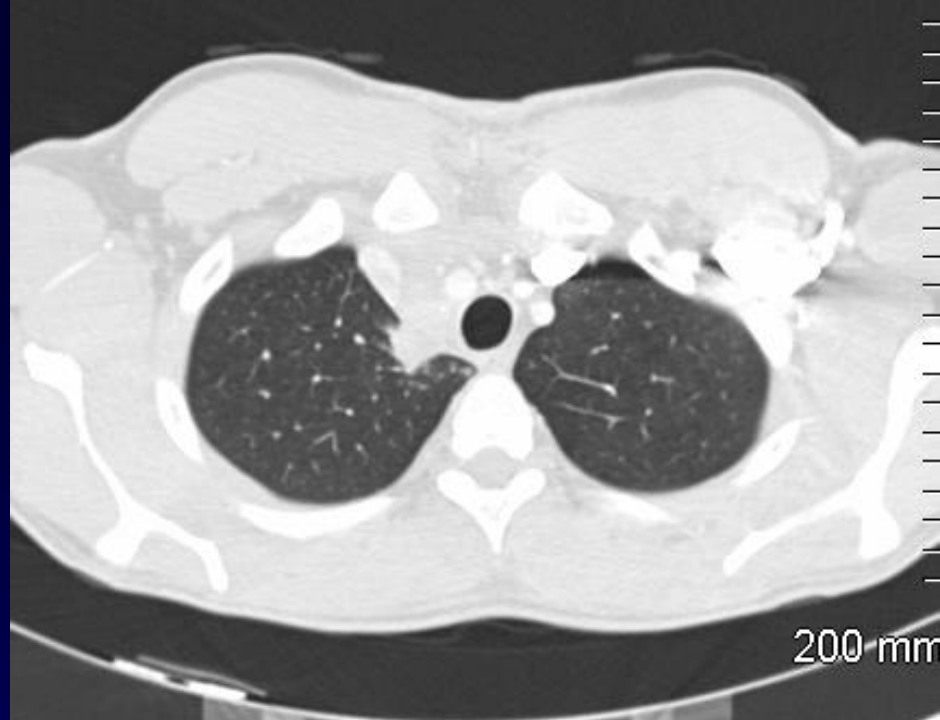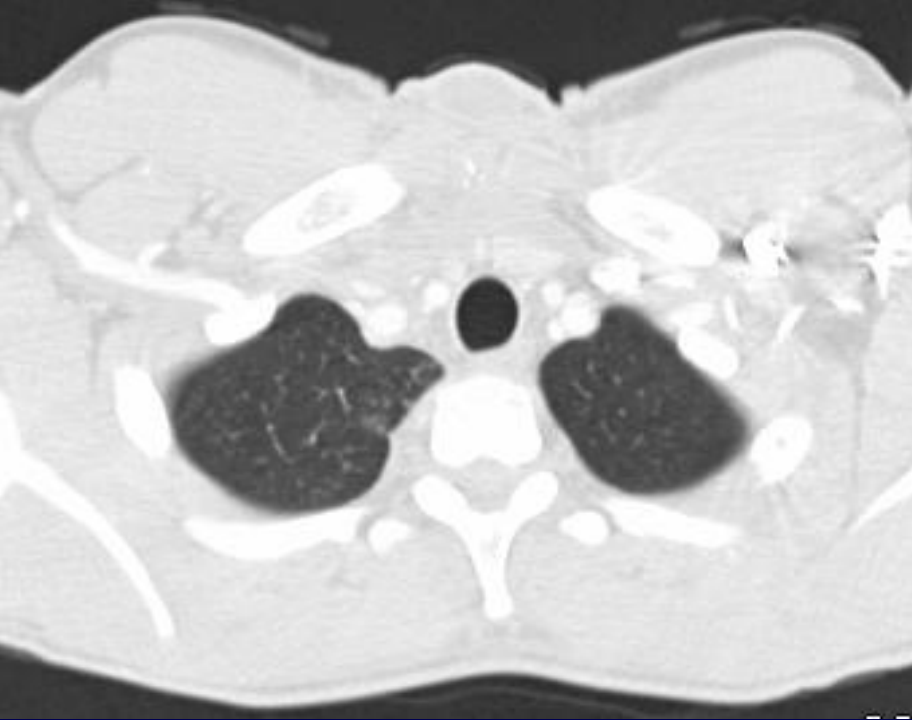
200 mm

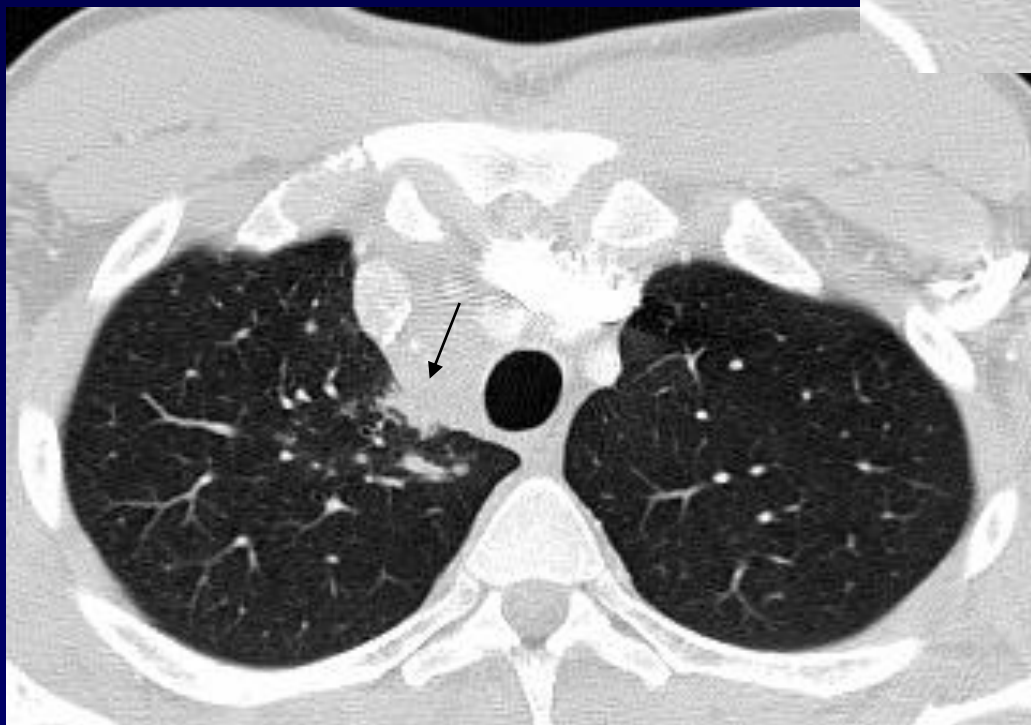
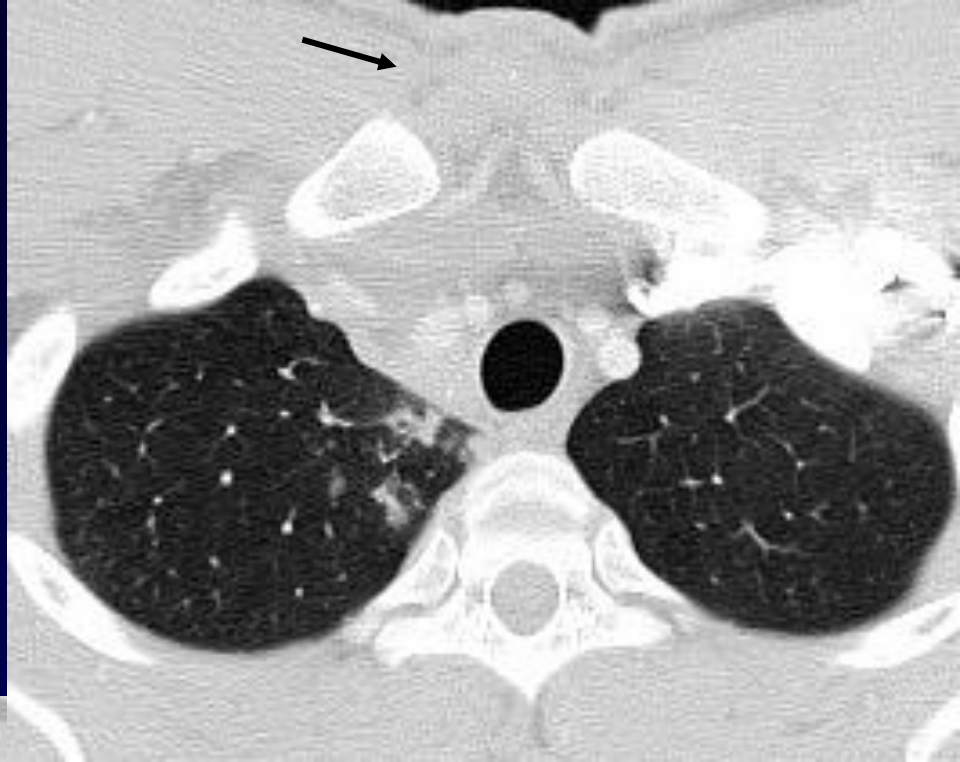
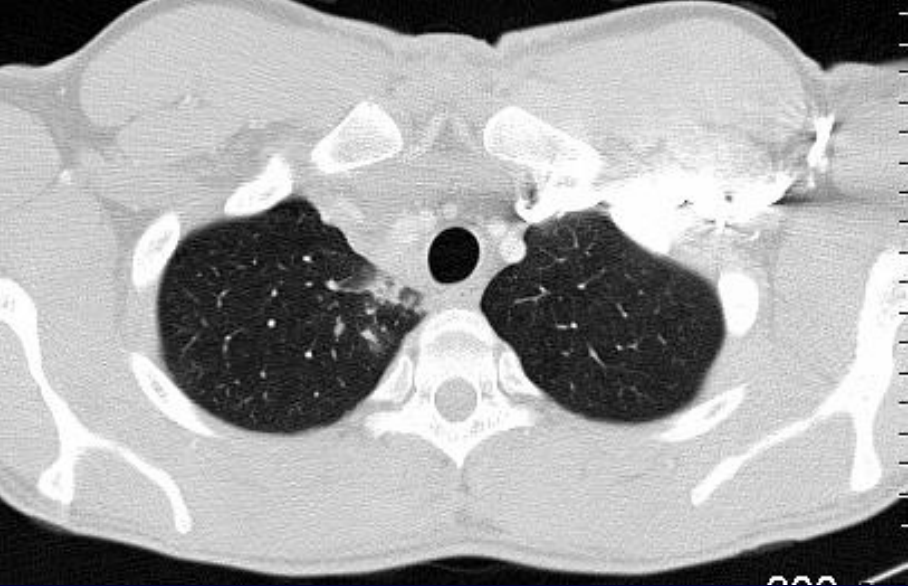


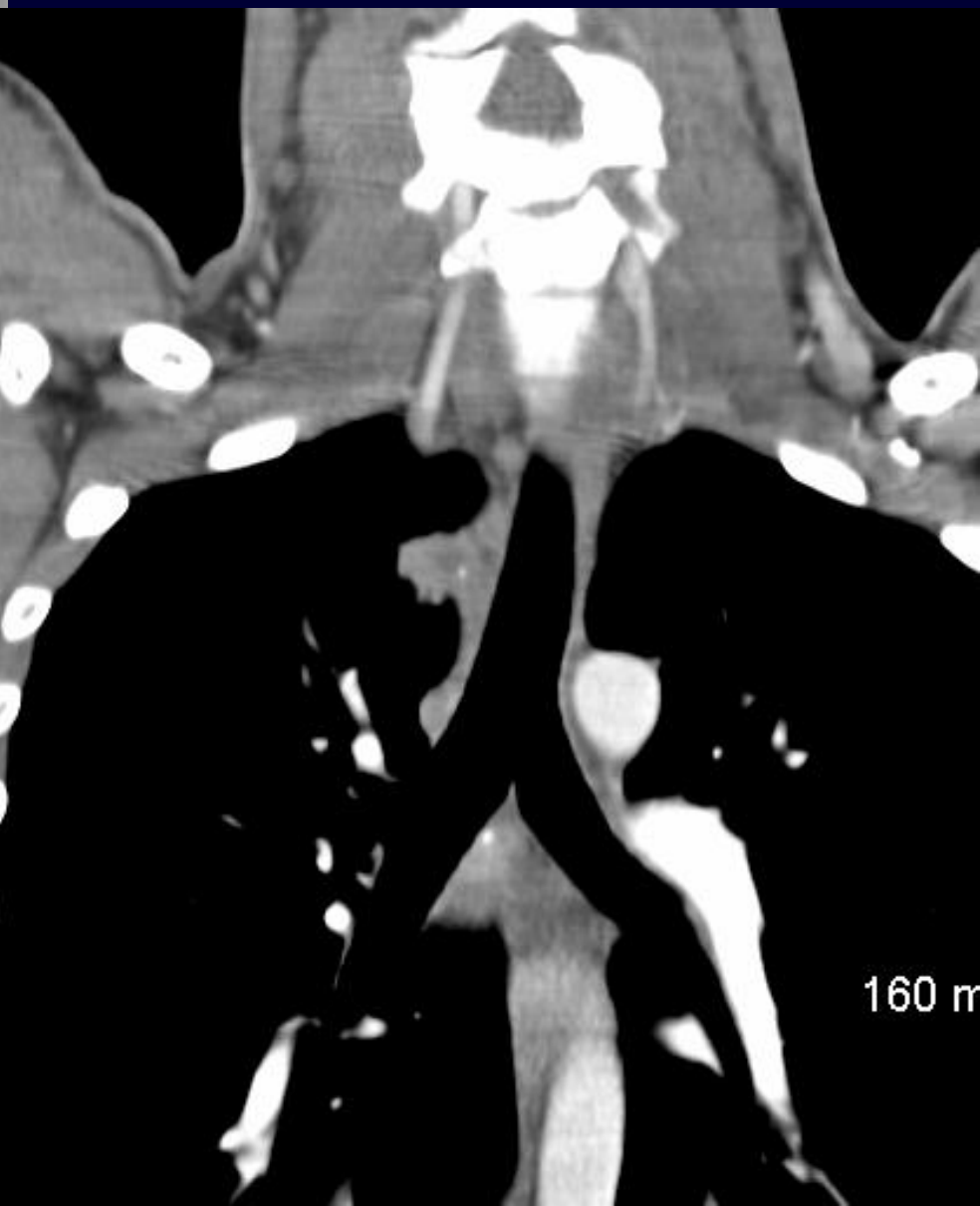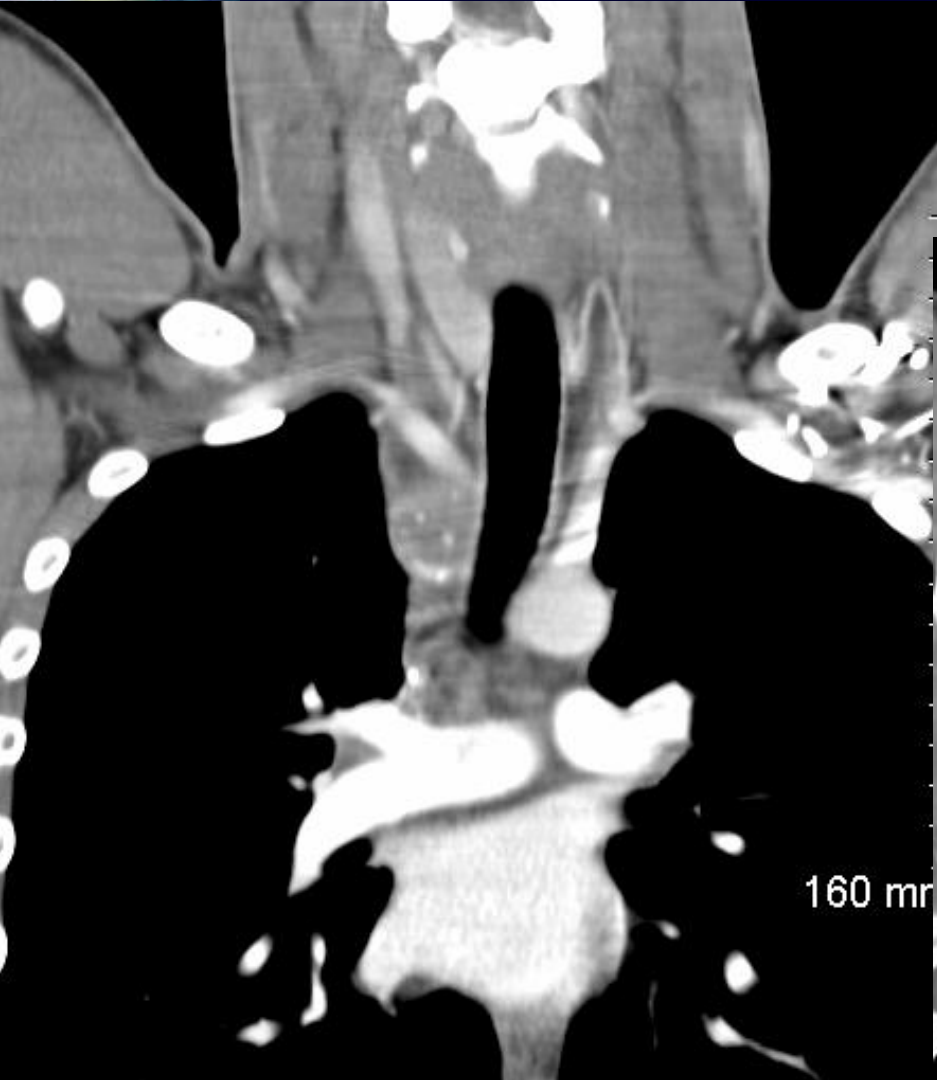?





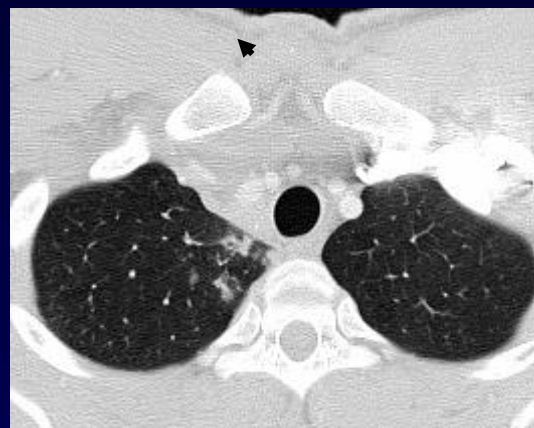
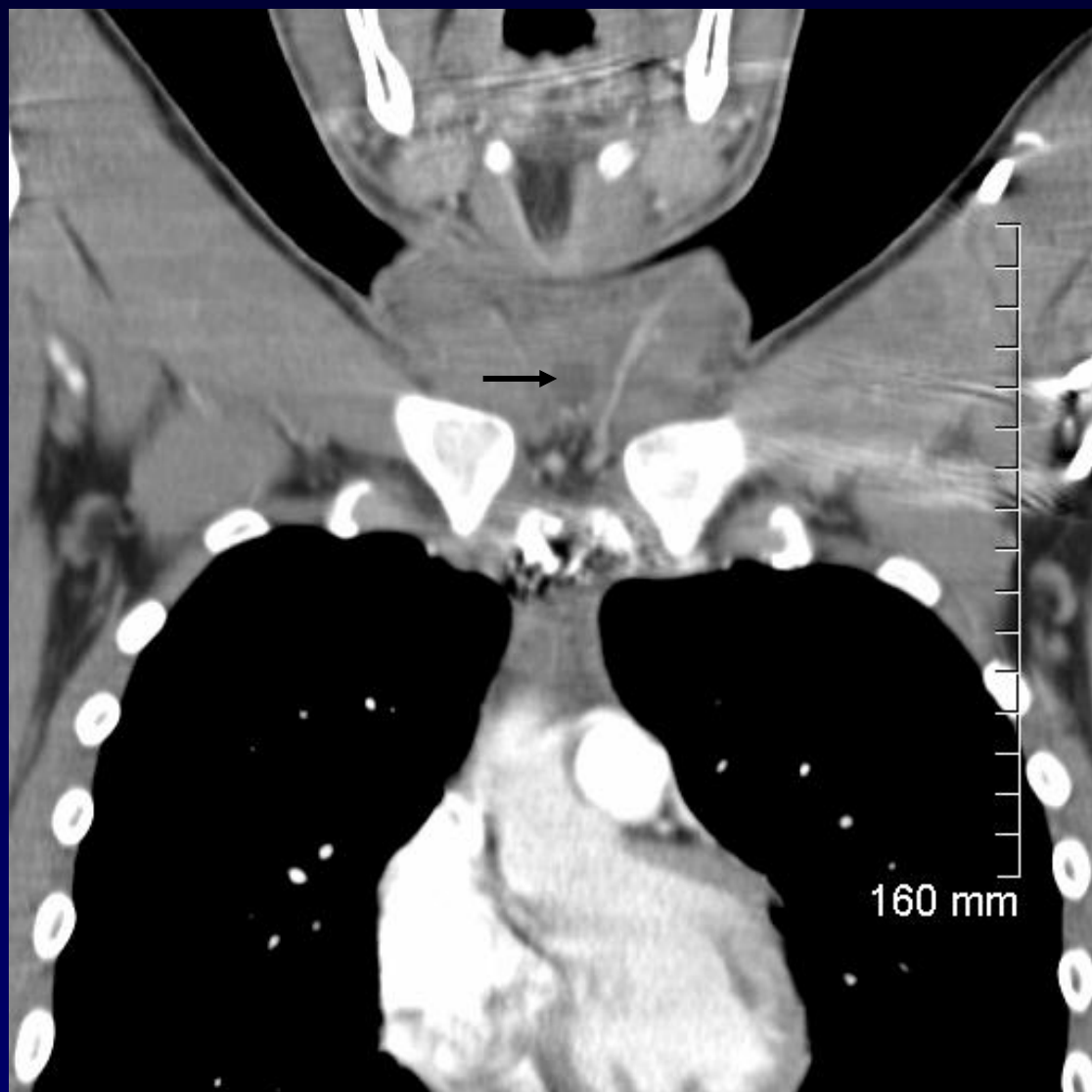


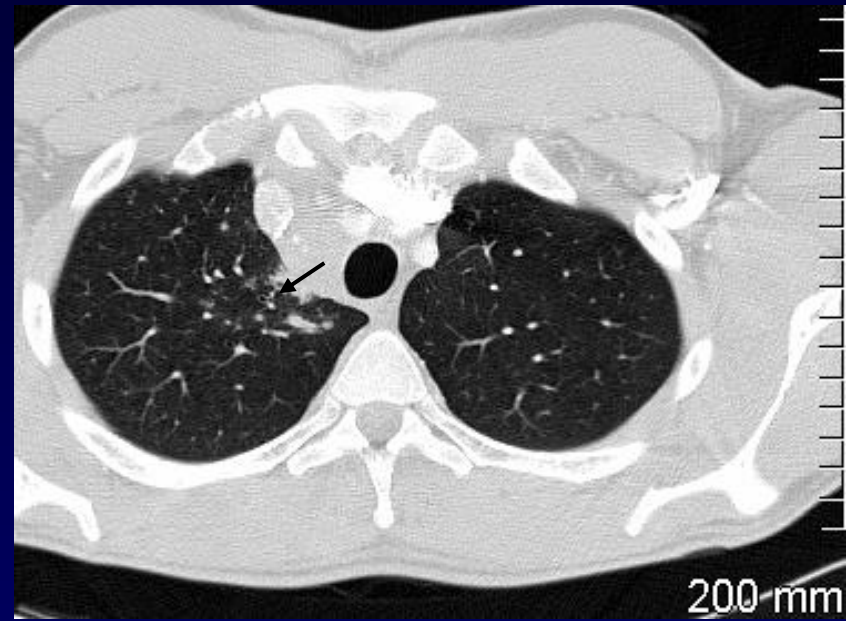
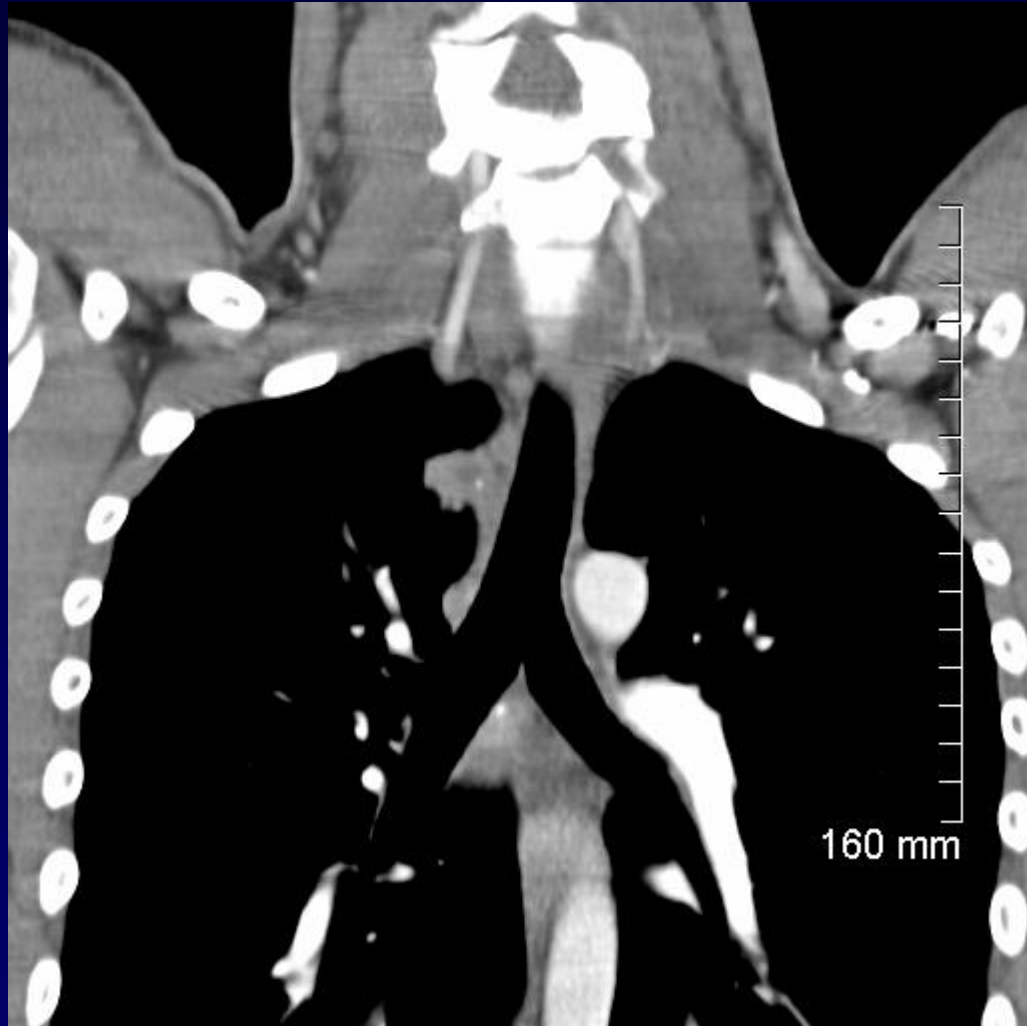






**Diagnostic ?**

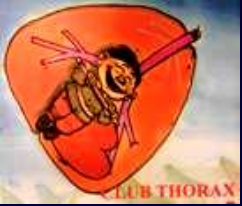





# DIAGNOSTIC

**PBT « au cou » et ... 3 Tubages BK**



# Diagnostic

**Tuberculose ganglionnaire**

(« écouelles » basses )

**Ponction-diagnostic / ggl ...« au palper »**

**Poumon en cours de pénétration ...?**

